

Fatal Cerebral Vasculitis Following Streptococcus Pneumoniae Meningitis

Van de Velde M¹, Duprez T² and Hantson P^{1,3*}

¹Department of Intensive Care, Cliniques St-Luc, University catholique de Louvain, Belgium

²Department of Neuroradiology, Cliniques St-Luc, University catholique de Louvain, Belgium

³Louvain Centre for Toxicology and Applied Pharmacology, University catholique de Louvain, Belgium

*Corresponding author:

Philippe Hantson,
Department of Intensive Care, Cliniques
Universitaires St-Luc, Avenue Hippocrate,
10, 1200 Brussels, Belgium, Tel: 32-2-7642755;
Fax:32-2-7648928;
E-mail: philippe.hantson@uclouvain.be

Received: 19 Nov 2022

Accepted: 26 Dec 2022

Published: 03 Jan 2023

J Short Name: JCMI

Copyright:

©2022 Hantson P, This is an open access article distributed under the terms of the Creative Commons Attribution License, which permits unrestricted use, distribution, and build upon your work non-commercially.

Citation:

Hantson P, Fatal Cerebral Vasculitis Following Streptococcus Pneumoniae Meningitis. J Clin Med Img. 2022; V6(21): 1-2

Keywords:

Hemiplegia; GCS; Hemodynamically

1. Clinical Image

A 68-year-old man was admitted to the Emergency Department for fever and altered consciousness (Glasgow Coma Scale (GCS) score 12/15, E4V2M6). Neurological examination revealed neck stiffness, aphasia, dysarthria and left-sided hemiplegia. Lumbar puncture yielded cloudy cerebrospinal fluid (CSF) with white blood cells (WBC) 282/mm³, neutrophils 92%, protein 857 mg/dL, glucose < 3 mg/dL, lactate 27.2 mmol/L. Contrast-enhanced brain computed tomography (CT) was unremarkable. Blood and CSF culture isolated penicillin-sensitive Streptococcus pneumoniae. The patient remained hemodynamically stable. Treatment with ceftriaxone (2000 mg twice a day) was started for a total duration of 14 days, in association with dexamethasone 10 mg four times daily over the first 4 days. Neurological improvement was noted within the first 48 hours, with a regression of aphasia and hemiplegia. An initial brain magnetic resonance imaging (MRI)

on day 6 failed to reveal significant ischemic lesions even on diffusion-weighted views. However, neurological status gradually worsened from day 7 and a follow-up brain MRI was performed on day 12 when GCS was 3/15 and revealed meningeal thickening and extensive ischaemic injury of the brain parenchyma (Figure 1). Palliative care was decided.

Delayed cerebral ischemia is an uncommon complication of S. pneumoniae meningitis which may occur during the second week of treatment in some patients who showed initially a clinical improvement after the initiation of the antimicrobial therapy [1]. Several processes have been hypothesized to explain the condition, including cerebral vasculitis, immune-mediated microangiopathy, rebound effect of the primary inflammatory reaction which had been initially suppressed by dexamethasone, and hypercoagulability [2,3]. The reintroduction of corticosteroids is followed by inconstant results and the final neurological prognosis is usually poor.

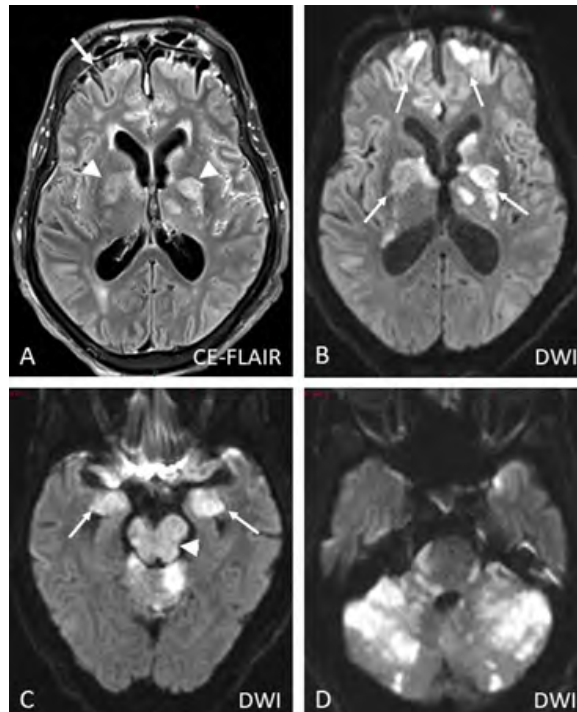


Figure 1: Magnetic resonance (MR) examination at critical phase

A : transverse contrast enhanced (CE) fluid-attenuated Inversion-Recovery (FLAIR) view showing strongly abnormal enhancement of pial bridging veins (arrow) and ischaemic injury of central grey nuclei (arrowheads).

B : transverse diffusion-weighted (DW) view in similar slice location as A best depicting ischaemic cytotoxic oedema within frontal cortex and central grey nuclei (arrows)

C : transverse DW view revealing complete infarction of the mesencephalon (arrowhead), together with that of temporal amygdalian gyruses (arrows) and of upper part of the cerebellar vermis (not arrowed)

D : transverse DW view revealing huge ischaemic injury of both cerebral hemispheres and at a lesser degree of the pons

References

1. Wittebole X, Duprez T, Hantson P. Delayed cerebral ischaemic injury following apparent recovery from *Streptococcus pneumoniae* meningitis. *Acta Clin Belg.* 2016; 71(5): 343-346.
2. Khedher A, Sma N, Slama D, Fraj N, Hachfi W, Boussarsar M. Cerebral Vasculitis Complicating Pneumococcal Meningitis. *Eur J Case Rep Intern Med.* 2018; 5(5): 000819.
3. Kato Y, Takeda H, Dembo T, Tanahashi N. Delayed recurrent ischemic stroke after initial good recovery from pneumococcal meningitis. *Intern Med.* 2012; 51: 647-50.